

IMPROVEMENT OF ECG CHANGES IN PATIENTS WITH CHOLELITHIASIS AFTER CHOLECYSTECTOMY

*Randa Z.A.M. Khair¹, Mohamed T.M.M. Ibrahim¹ and Numan M.A. Malik²

¹Department of Surgery, ²Department of Anaesthesiology, University of Khartoum
E-mail: randazaki@uofk.edu (*Corresponding Author)

Abstract:

Background: different non-cardiac conditions like cholecystitis, pancreatitis, pneumonitis, gastric distension have been reported to mimic heart disease both clinically and electrocardiographically.

Aims: to study the ECG changes in the perioperative period in patients with gallbladder disease and to compare these changes.

Patients and methods: a total number of 76 patients with symptomatic gallbladder disease are included in this study. All patients underwent open cholecystectomy. Pre- and post-operative ECG reports are studied and compared.

Results: the majority of the patients (88.2%) have changes in the preoperative ECG reports. Among those changes, the ischemic changes were more common than the non-ischemic (74.4% vs 53.8%). Most of these preoperative changes disappeared in the postoperative ECG reports; in 51.7% of the ischemic and 78.6% of the non-ischemic.

Conclusion:

ECG in patients with gallbladder disease may show some ischemic and other non-ischemic changes. Most of these changes either disappear or remain static in the postoperative ECG.

Introduction

Ischemic ECG changes have been observed in patients with gallbladder disease with no underlying cardiac problem. Such changes necessitate, sometimes, postponing the surgery, referral to physician cardiologist and or requesting echocardiogram. Some of these changes disappeared postoperatively.

Different non cardiac conditions have been reported to mimic ischaemic heart disease and angina pectoris clinically. Some of these conditions have been reported to cause ECG changes similar to those occur in cardiac ischaemia^{1,2}. Examples of such diseases include cholecystitis^{1,3,4,5,6} pancreatitis^{1,7,8,9} pneumonitis^{1,10}.

Gastric distension and acute cholecystitis may lead to chest pain and ECG changes and hence are not differentiated clinically from cardiac ischemia^{1,11}. Some of these conditions are found

to be associated with ECG changes, that mimic ischemic heart disease, such as ST-segment elevation^{1,4}.

Differentiation of such non-cardiac conditions will improve the diagnosis and clinical care, avoid the complication of unnecessary cardiac management and will lead to reduction of morbidity and mortality caused by incorrect thrombolysis and angioplasty^{1,2}. This difficulty in differentiation may subject the patients with angina pectoris or acute coronary occlusion to unnecessary surgical intervention and hence more imperative surgical catastrophe².

In addition to the problem of mimicry, there was a belief, among both surgeons and internist, that actual heart disease may either be initiated or aggravated by chronic gallbladder disease². Surgical removal of gallbladder had been followed by restoration of cardiac compensation in some patients of congestive heart failure, restoration of normal rhythm in others and improvement or cure in some patients of angina pectoris who first seemed to suffer major attack of coronary occlusion².

Fitz-Hugh T and Wolferth CC in 1935 reported six patients with cardiac symptoms associated with ischaemic ECG changes with cardiac improvement following cholecystectomy².

Objectives

To study the ECG changes in patients with symptomatic gallbladder disease and to compare the pre-operative with the post-operative ECG reports.

Patients and Methods

This is a cross-sectional descriptive prospective study. The study area is University of Khartoum Medical and Health Services Centre which is the health insurance centre for the staff, workers and academic and non-academic staff, of the University of Khartoum and their families and the university students. The centre has a capacity of 16 surgical beds.

Seventy six (76) patients with symptomatic gallbladder disease, diagnosed clinically and sonographically were included in this study. The patients were selected randomly.

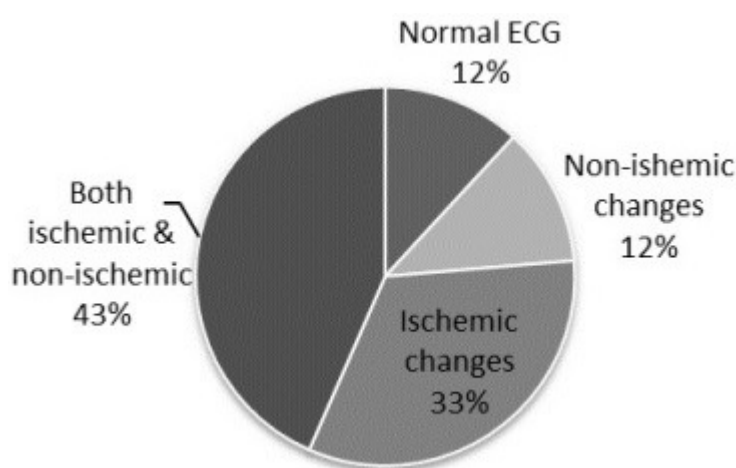
Exclusion criterion is patients with known cardiac ischemia. Three other patients were excluded because of lost ECG reports either pre- or post-operatively.

Patients were consented to be included in the research. A questionnaire form was filled for patients' data; included age, gender, presenting symptoms, past history, pulse, blood pressure and abdominal signs. All patients underwent cholecystectomy after clinical and sonographic evidence that there was no acute hepatobiliary inflammation. For the latter, patients with

acute cholecystitis had surgery after, at least three months of the clearance of the inflammation. All patients had ECG before surgery, on the first or second postoperative day and two weeks after surgery. The ECG changes were divided into non-ischemic changes (delay or failure of reconfiguration in the leads V1- V6), ischemic changes (flat or depressed t-wave, depressed ST segment or both).

Results

The total number of patients is seventy six (76); twelve are males and 64 females with a male to female ratio of 1: 5. The age is ranging from 25- 77 years with mean age 44.1 (\pm 11.9) years. Preoperatively, 70 patients were not known to have hypertension; six of them had significantly high blood pressure reading preoperatively in the OR (Operating Room). Preoperatively, 9 patients had normal ECG and total of 67 patients had preoperative ECG changes; 9 had only non-ischemic changes, 25 had only ischemic and 33 had both changes (Figure 1). Regarding the postoperative ECG; out of the 42 patients who had preoperative non-ischemic changes, the changes disappeared in 33 patients, in 6 of them these changes remained as in the preoperative ECG records, 3 had more changes and other 3 developed non ischemic ECG changes postoperatively. Fifty eight patients had ischemic changes in the preoperative ECG; of them 30 improved, 11 remained, 17 deteriorated and 6 patients had developed ECG ischemic changes postoperatively.



Preoperative ECG Changes (No. 76)

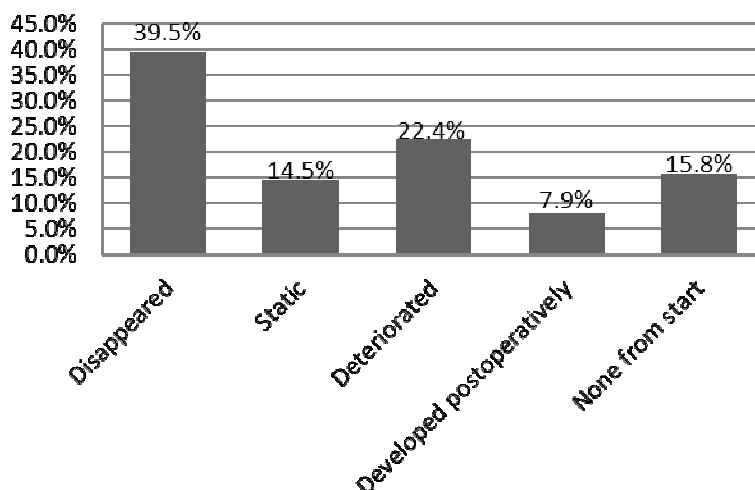


Figure 2: Postoperative ECG ischemic changes (No. 76)

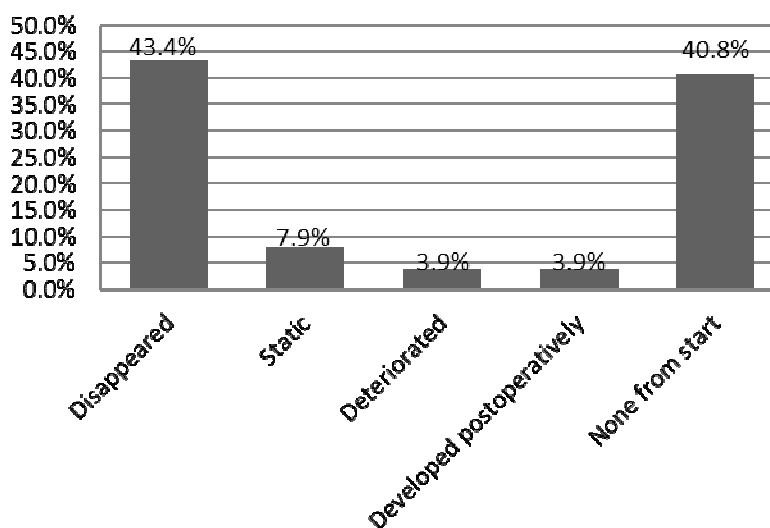


Figure 3: Postoperative non-ischemic ECG change (No. 76)

Discussion

Out of the 76 patients included in this study, preoperative electrocardiographic changes are reported in 67 patients (88.2%); the ischemic changes represent the majority, 86.6% of them, either isolated or combined with other changes. Hepatobiliary system inflammation may produce some ECG changes e.g non-specific ST-T wave changes^{1,5}.

All patients in this study have symptomatic gallbladder disease. Symptoms are related most likely to gallstones or recurrent cholecystitis or both reasons but none of them underwent cholecystectomy for acute inflammation. The reason for the ECG changes may be due to the irritation of the surrounding caused by inflamed gallbladder, which leads to creation of reflex autonomic stimuli that will restrict the coronary blood supply¹. But that does not explain

whether that will be permanent or transient; and for how long will these changes remain in relation to the subsidence and or severity of inflammation.

Gallbladder distension leads to increase heart rate and arterial blood pressure^{1,2}. Studies in animals suggested that the distension of the gallbladder has an effect on the coronary blood flow and that may be the factor leading to the ECG changes^{1,2,6}. Only six (7.9%) of the patients in this study were known hypertensive but, in addition to them, other twelve (15.8%) had transient preoperative high blood pressure reading. Most of this group (17 out of 18) are reported to have preoperative ECG changes. The ischemic changes, isolated or combined, are reported in 16 of them.

About half of the patients (51.7%) with ischemic ECG changes showed disappearance of the changes in the immediate postoperative ECG which persisted in the consequent ECG two weeks after. The ischemic changes showed more improvement in the postoperative ECG when they are combined with other changes than when isolated (60.6% vs 40.0%); but still none of them had postoperative cardiac symptoms or complications.

Patel N et al in 2011 reported a 34-year-old female with ST-segment elevation, with no previous cardiac history, as the youngest reported case in the literature; compared to the previously reported 5 patients^{1,3}.

In our series other ECG changes, in addition to the ischemic changes, were detected; namely delayed or failure of reconfiguration mainly in V2, V3 and V4 leads. Such non-specific changes are detected in 55.3% of the patients and in the majority of them (78.6%) these changes disappeared postoperatively. The ECG changes that are associated with gallbladder disease have been noticed since 1878 when diffuse, non-specific changes together with ischemic changes namely T-wave inversions or ST-segment depressions were detected¹.

Detection of such ECG changes will minimize the delay in surgical management that may occur awaiting unnecessary cardiac investigations⁵. That will also improve clinical care and lead to avoidance of incorrect cardiac management¹.

In 3.9% of the patients, the postoperative ECG showed newly developed ischemic changes, while other 3.9% of the patients showed postoperative non-specific ECG changes and both were not explainable!

Conclusion

Ischemic and non-ischemic ECG changes were detected in 88.2% of patients with symptomatic gallbladder disease with no history of cardiac disease. Most of these changes

either disappeared or remained static in the postoperative ECG without consequent cardiac complications; which reflects that not all ECG changes do indicate, necessarily, cardiac problem.

Another study involving larger number of patients is recommended in order to detect the patients at risk.

Acknowledgement

We would like to acknowledge Dr Suhaila A Sharif, Mr Seif H AlSanousi, Mr FathAlRahman G Agbar, Ms Intisar H, Mr Aidrous E ElSheikh, Ms Aaisha AbdelHakim, Ms Suhair S Sabir, Ms Wigdan A Hassan, Ms Faigha A Mohamed, Ms Amira A Mohamed, Ms Samia M Salih, Mr Ibrahim M Ibrahim and Mr AbdelHamid AbdelRahman for their real participation in the study.

References

- [1] Patel N, Ariyathenam A, Davies W, Harris A. Acute Cholecystitis Leading to Ischemic ECG Changes in a Patient with No Underlying Cardiac Disease. *JSLs* 2011;15:105-108.
- [2] Fitz-Hugh T, Wlferth CC. Cardiac improvement following gallbladder surgery: electrocardiographic evidence in cases with associated myocardial disease. *Ann Surg* 1935;101:478-483.
- [3] Nasir JM. Chest pain and ST segment elevation attributable to cholecystitis: a case report and review of the literature. *Mil Med* 2006;171(12):1255-1258.
- [4] Kransa MJ, Flancbaum I. Electrocardiographic changes in cardiac patients with acute gallbladder disease. *Am Surg* 1986;52:541-543.
- [5] Dickerman JL. Electrocardiographic changes in cardiac patients with acute gallbladder disease. *Am Surg* 1986;52:541-545.
- [6] Molinari C, Grossini E, Mary DA, Vacca G. effects of distension of the gallbladder on plasma renin activity in anesthetized pigs. *Circulation* 2000;101:2539-2545.
- [7] Pezzilli R, Barakat B, Billi P, Bertacclnl B. Electrocardiographic abnormalities in acute pancreatitis. *Eur J Emerg Med* 1999;6:27-29.
- [8] Patel J, Movahed A, Reeves WC. Electrocardiographic and segmental wall motion abnormalities in pancreatitis mimicking myocardial infarction. *Clin cardiol* 1994;17:505-509.
- [9] Variyam EP, Shah A. Pericardial effusion and left ventricular function in patients with acute alcoholic pancreatitis. *Arch Intern Med* 1987;47:923-925.

[10] Seedar MA, Feldman C, Skoulargis J, Promniz DA, Smith C, Zwi S. A study of acute community-acquired pneumonia, including details of cardiac changes. *Q J Med* 1993;86:669-675.

[11] Fraiss MA, Rodgers K. Dramatic electrocardiographic T-wave changes associated with gastric dilatation. *Chest* 1990;98:489-490.