

See discussions, stats, and author profiles for this publication at: <https://www.researchgate.net/publication/281109310>

# Mursal, W.I and Saad ,.A.M.(2010) Aflatoxicosis in broilers in Khartoum State Uof K. J.of Vet Med and Anim Prod 1(2)3-14

Article · January 2010

---

READS

3

2 authors, including:



[Amir mustafa Saad](#)

University of Khartoum

30 PUBLICATIONS 209 CITATIONS

[SEE PROFILE](#)

## AFLATOXICOSIS IN BROILERS IN KHARTOUM STATE

Wael. I. Mursal<sup>1</sup> and Amir.M.Saad<sup>2</sup>

<sup>1</sup> Faculty of Vet Science, University of Bahr Elgazal

<sup>2</sup> Faculty of Vet Medicine, University of Khartoum

### المستخلص

اجريت هذه الدراسة للكشف عن وجود الأفلاتوكسين و تحديد تركيزه في علائق الدجاج اللحم و أكباده مع توضيح تأثيرات هذه السموم المرضية على الكبد.

تم جمع ١٠٠ عينة عليقة(العليقة الكاملة النهائية، أمباز الفول السوداني و الذرة) و ١٠٠ عينة كبد بصورة عشوائية من ١٠ مزارع للدجاج اللحم بولاية الخرطوم. بعد عملية إستخلاص الأفلاتوكسين من العلائق و الأكباد تم القياس بإستخدام إختبار الإليزا.

وجد أن جميع عينات العلائق تحتوي على الأفلاتوكسين، تراوح تركيز الأفلاتوكسين في عينات العليقة النهائية (٦٠ عينة) بين ١٠ – ٩٧ جزء من البليون بمتوسط ٤٥.٥ جزء من البليون، بينما كان تركيزه في عينات أمباز الفول السوداني (٢٠ عينة) بين ٤٨ – ١٠٩ جزء من البليون بمتوسط ٩١.٤ جزء من البليون وكان تركيزه في عينات الذرة (٢٠ عينة) بين ٧ – ١٠ جزء من البليون بمتوسط ٩.٣ جزء من البليون. وجد أن ١٧ عينة من عينات الكبد تحتوي على بقايا من الأفلاتوكسين تراوحت بين ٢ – ١٢ جزء من البليون بمتوسط ٤.٩ جزء من البليون.

أشتملت التغيرات المرضية العيانية في عينات الكبد المصابة على مناطق نزائف كبيرة، تضخم و شحوب بالإضافة للإحتقان و النخر. التغيرات المرضية النسيجية أشتملت على إحتقان الأوردة المركزية، نزائف، فراغات سيتوبلازمية(تنكس إستسفاي)، نخر و إرتشاح ليمفاوي في شكل عقيدات.

## Abstract

The occurrence and concentration of aflatoxins in broilers feedstuff and livers were investigated and their toxicopathological changes in the liver were described.

100 samples of feed including (Finished Total ration, groundnut cake and dura (sorghum)) and 100 liver samples were collected randomly from 10 poultry (broiler) farms in Khartoum state. After extraction, the aflatoxins were detected using ELISA test.

Aflatoxins were detected in all feedstuff samples collected. The concentrations in total finished ration samples (60) varied between 10 and 97 ppb with a mean of 45.5 ppb, groundnut cake samples (20) ranged between 84 and 109 ppb with a mean of 91.4 ppb and in dura (sorghum) samples (20) varied between 7 and 10 ppb with a mean of 9.3 ppb.

Seventeen out of one hundred liver samples examined were positive for aflatoxins residues and the concentrations varied between 2 and 12 ppb with a mean of 4.9 ppb.

The affected liver showed hepatomegaly, paleness, wide areas of hemorrhages and necrosis. Histopathology revealed congestion of central vein, hemorrhages, vacuolar degeneration, necrosis and nodular lymphoid infiltration.

## Introduction

Aflatoxins (AF) are a group of heterocyclic toxic metabolites of toxigenic fungi *Aspergillus flavus* and *A. parasiticus*, (Diaz, 2005). They are difuranocoumarin derivatives produced by a polyketide pathway. Four major aflatoxins produced in feedstuffs and foods are aflatoxins B<sub>1</sub>, B<sub>2</sub>, G<sub>1</sub> and G<sub>2</sub>. The most potent and the most frequently occurring of the four compounds is aflatoxin B<sub>1</sub>. Aflatoxin M<sub>1</sub> is a metabolite of aflatoxin B<sub>1</sub> that occurs in various animal tissues and fluids from animals. Infection and production of aflatoxins in field crops by species is often associated with drought stress and insect damage (Richard *et al.*, 1993). When AF is ingested by animals, it is readily absorbed via the gastrointestinal tract into the portal blood and is carried to the liver where it is metabolized. (Hsieh, 1983). The main lesions of aflatoxicosis in birds appear in the liver which shows periportal necrosis with bile duct proliferation and fibrosis, jaundice, generalized oedema and hemorrhages, and depletion of lymphoid organs. (Charlton, 2006).

Very little information is available regarding poultry aflatoxicosis in Khartoum state .Hence this study is an attempt to evaluate the magnitude of poultry aflatoxicosis and examine the interrelationship of aflatoxins to poultry health and production

## **Materials and Methods**

### **Samples collection:**

The samples were collected randomly from 10 poultry (broiler) farms of different capacities i.e. Farms A, B and C), are big intensive farms (above 25.000 chicks) located in Khartoum municipality. Farms E, F and G are medium farms (5.000 - 15.000 chicks are located in Khartoum North municipality. Farm D which is an intensive farm and farms H, I and J which are small extensive farms (less than 5.000 chicks ) are located in Omdurman municipality .

### **Feedstuff samples:**

100 samples, each weighing 250gm were obtained, i.e. 10 samples were taken from each farm. These samples comprised 6 samples finished ration, 2 samples groundnut cake and 2 samples Dura (Sorghum). Finished ration samples collected included, two samples each, from recently prepared ration, from feeders and from sacs in the stores.

### **Liver samples:**

100 liver samples were collected from the 10 farms (10 samples each) immediately after slaughtering. Each sample was divided into two parts, the first one was blended and stored at -20°C for ELISA test and the other one was kept in 10% formol saline for histopathological examination.

### **Samples Extraction:**

#### **Feedstuff samples:**

This was done according to manufacturer instruction (GIPSA FGIS 2005-12, Neogen Corporation USA/Canada).Samples were grounded using high speed blender for 5 min, 25 ml of 70% methanol was added to 5gm of the grounded sample, and shaken vigorously for 3 min. The extract was then filtered using whattman filter paper.

**Liver samples:**

Liver extracts were done according to Gathumbi *et al.* (2003). 5 ml of Ice-cold (-18°C) methanol 5%-acetone10% (50:50) were added to 2 gram of blended liver tissue, the mixture was homogenized for 5 min using a magnetic stirrer. The homogenate was then placed at (-18°C) for 20 min, before 5 mL of Phosphate Buffered Saline (PBS) was added and a further 30-min homogenization on a magnetic stirrer was carried out. The homogenate was centrifuged at 1500 rpm for 15 min and the supernatant was recovered. (0.5 mL) of the supernatant was diluted 1:5 in PBS and defatted by homogenization for 30s with(5 mL) 10% *n*-heptane followed by a 5 min centrifugation at 2000 rpm and then the lower methanol-acetone-PBS layer was recovered This extract was stored at 2 - 8°C until analyzed.

**Enzyme linked Immuno-sorbent Assay (ELISA):**

**Assay principles:**

The aflatoxins concentration in both feedstuff and liver extracts was measured using Veratox® aflatoxins quantitative kits (GIPSA FGIS 2005-12, Neogen Corporation USA/Canada).

**Histopathological Techniques:**

The liver specimens for histopathology were taken soon after slaughtering and kept in 10% formol saline ,processed and sections 4-5µ were prepared and stained with haematoxyline and eosin (Culling, 1974).

## **Results**

**Feedstuff:**

**Finished ration samples:**

Aflatoxins were detected in all finished ration samples (60). The concentrations varied between 10 and 97 ppb with a mean of 45.5 ppb (Table 1)..

**Recently purchased ration samples:**

The mean concentration was calculated as  $35 \pm 13.4$  ppb. Farm J scored the highest concentration i.e. 57 ppb where as farm C showed the lowest concentration of 10 ppb (Table 1).

**Stored ration samples:**

The mean concentration was calculated as  $52.5 \pm 25.8$  ppb. Farm H and I scored the highest concentration i.e. 97 ppb where as farm C showed the lowest concentration 13 ppb (Table 1).

**Samples taken from feeders:**

The mean concentration was calculated as  $50 \pm 21.3$  ppb. Farm D scored the highest concentration i.e. 97 ppb where as farm G showed the lowest concentration 12 ppb (Table 1).

**Groundnut cake samples:**

Aflatoxins were detected in all samples collected (20), and the concentrations ranged between 72 and 120 ppb with a mean of  $94.1 \pm 13.6$  ppb (Table 1).

**Dura (Sorghum) samples:**

Aflatoxins were detected in all samples collected (20), and the concentrations varied between 7 and 12 ppb with a mean of  $9.3 \pm 1.3$  ppb (Table 1).

**Liver samples:**

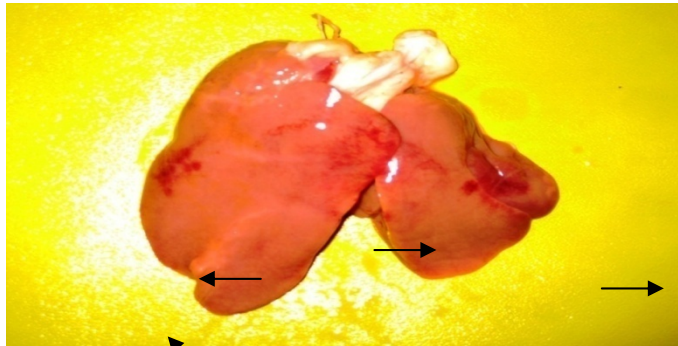
Seventeen out of one hundred liver samples examined were found positive to aflatoxins. The positive liver samples were found in all farms examined (10) except farm B and C. Aflatoxins residues varied between 2 ppb in farm D, E and J and 12 ppb in Farm J with a mean of  $4.9 \pm 2.9$  ppb. ix out of 10 samples were positive in farm J (Table 1).

**Gross lesions:**

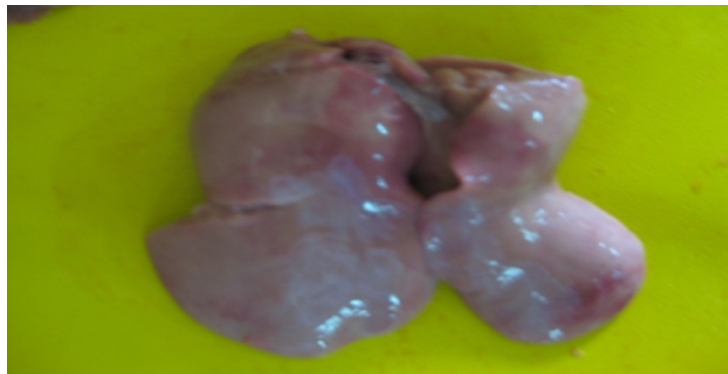Some livers showed wide areas of hemorrhage (Fig 1), hepatomegaly and paleness (Fig 2). Others revealed marked congestion and necrosis.

**Histopathological findings:**

The liver showed congestion of central vein, diffuse hemorrhages and necrosis (Fig 3), hydropic degeneration of the hepatocytes (Fig 4) and lymphoid nodules .



**Fig: 1.** Liver showing wide areas of hemorrhages. (Farm H), 5 ppb aflatoxins residue in the liver.



**Fig: 2.** The right lobe of the liver is larger than the normal left.  
- Both of them are pale in color.  
(Farm I), 10 ppb. Aflatoxins residue in the liver was

Table. 1: Concentration of Aflatoxins in feedstuff and liver samples (ppb).

Farm	Finished ration						Peanut cake		Dura (Sorghum)		Liver samples	
	Purchased recently		Stored		From feeders		S <sub>1</sub>	S <sub>2</sub>	S <sub>1</sub>	S <sub>2</sub>	NO. Positive samples	Concentration
	S <sub>1</sub>	S <sub>2</sub>	S <sub>3</sub>	S <sub>4</sub>	S <sub>5</sub>	S <sub>6</sub>						
Big intensive farms												
A	38	47	40	48	38	48	84	86	7	10	1	3
B	37	39	39	48	36	47	104	88	10	8	0	0
C	10	18	13	14	46	72	85	109	10	10	0	0
Medium farms												
E	20	27	18	52	50	40	87	89	8	10	3	2, 2, 5
F	38	38	30	51	61	58	75	86	7	9	1	4
G	50	38	46	40	12	28	84	93	12	10	1	4
Small extensive farms												
D	50	48	72	96	97	75	89	96	9	8	1	2
H	26	16	97	40	27	48	118	97	9	12	2	5, 5
I	13	36	97	73	60	27	120	117	9	10	2	4, 10
J	57	37	70	66	60	68	98	72	9	9	6	2, 4, 4, 5, 10, 12

Key: S= sample.



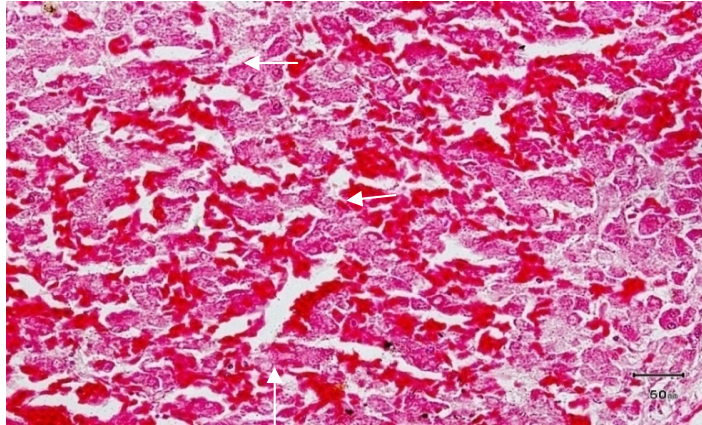


Fig. 3 -Liver showing hemorrhages and necrosis as judged by disappearance of nuclei and cytoplasmic changes.  
(Farm (J), 12 ppb aflatoxins residues in the liver H & E 400 X

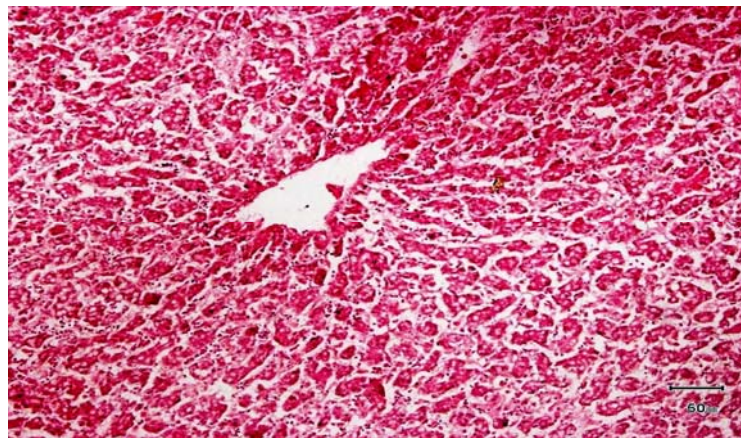


Fig. 4 liver showing Cytoplasmic vacuolation of hepatocytes.  
(Farm I), 10 ppb aflatoxins residues in the liver . H & E 400 X

## Discussion

Aflatoxins contamination can occur in a wide variety of feedstuffs including corn, sorghum, wheat, groundnuts, soya, rice, cottonseed and various derivative products made from these primary feedstuffs (Busby and Wogan, 1979).

No significant differences in the mean aflatoxins concentration between the samples collected from the feeders (50 ppb) those collected from stores (52 ppb) or that purchased recently (35 ppb). This could be attributed to that the upper limit of the range in some samples collected from feeders and stores were found to be high. In a survey conducted in India in different poultry farms, Banerjee and Shetty, (1992), reported concentrations of aflatoxins in feedstuff samples ranging between 5.5 and 90 ppb which is relatively nearer to our result (10 – 97 ppb). The maximum aflatoxins level in the broiler feedstuff (97 ppb) in this study is higher than the value in poultry feedstuff (50 ppb) reported by Oruc *et al.*, (2007) in Turkey and lower than the value reported by Dawlatana *et al.*, (2002) in Bangladesh (160 ppb).

This study showed that the concentration of aflatoxins in groundnut cake samples ranged between 72 and 120 ppb. This range is relatively narrow compared to the wide ranges (1-244 ppb) obtained by Yoshizawa, (1981) in Philippines. These differences could be attributed to the wide variation in climatic, environmental conditions and in differences in managerial levels between Sudan and Philippines. On the other hand ,aflatoxin concentration in sorghum samples obtained in the study is low (7-12ppb) Logrieco *et al.*, (2003) also found little or no aflatoxins in the sorghum samples they analyzed

In general aflatoxin levels currently reported in feed stuff are considered high according to the internationally accepted rule that growing poultry should not receive more than 20 ppb aflatoxins in the diet (Jones *et al.*, 1994). The liver is the mostly affected organ when poultry is fed aflatoxins (Charlton, 2006). This study showed that the concentrations of aflatoxins residues in liver samples varied between 2 and 12 ppb with a

mean of 4.9 ppb. In an experimental study Mintzlaff *et al.*, (1974) found that when the broiler chicks were fed rations containing aflatoxins at concentration of 15000 µg/kg for 8 weeks, aflatoxins residues in the liver tissue were 15 ppb. In another study Fernandez *et al.*, (1994) reported a range of 0.29 – 0.63 ppb aflatoxins residues in livers of broilers fed on aflatoxins contaminated feedstuff (5 mg/kg) for 32 days. This differs from our results and might be due to differences in exposure duration and concentration of aflatoxins in feedstuff and the breeds used. In this study, hepatomegaly, and paleness of the liver were seen in association with aflatoxins; this has been previously, observed by (Kumar and Balachandran, 2009), congestion and haemorrhage were also evident in most liver which agree with Lamont(1979). and Slowik *et al.*, (1985). As reported by Lawlor and Lynch, (2005) necrotic changes were recognized grossly in most samples examined.

The microscopic lesions of the liver revealed congestion of central vein, hemorrhages, slight to moderate cytoplasmic vacuolation (hydropic degeneration), necrosis and lymphoid nodules. Similar results were obtained by Hussain *et al.*, (2008) and Kumar and Balachandran, (2009) in their studies of experimental aflatoxicosis in broiler chicks.

Kohler, (1963) and Lanza, (1980) found fatty change, proliferation of bile ducts and cirrhosis in broiler livers exposed to 200 ppb of aflatoxins. These results are different from our results and could be attributed to the comparatively high levels of aflatoxins doses used in those studies.

### **Acknowledgment**

This work was conducted within the bounds of a research project fully financed by the Sudanese Standards and Metrology Organization(SSMO)

### **References**

- Banerjee, A. and Shetty, H. S. (1992). Microbial load in poultry feed and detection of Aflatoxins, using monoclonal antibody-based enzyme linked immunosorbent assay. Letters in Applied Microbiology. 15: 89-91.

- Busby, W. F. and Wogan, G. N. (1979). "Food-borne mycotoxins and alimentary mycotoxicosis" In: Food-borne infections and intoxications. 2nd ed., Riemann, H. and Bryan, F.L. eds., Academic press, New York: 537.
- Charlton, B.R. 2006. Avian Disease Manual (6th ed). American Association of Avian Pathologists. Athens, Georgia. USA. Pp 132.
- Culling, C. F. A. (1974). Handbook of histo-pathological and histo-chemical techniques. Butter Worth and Co, London.
- Dawlatana. M., Coker, R. D., Nagler, M. J., Wild, C. P., Hassan, M. S. and Blunden, G. (2002). The occurrence of mycotoxins in key commodities in Bangladesh: Surveillance results from 1993 to 1995. J. Nat. Tox.11 (4): 379-386.
- Diaz, D. E. (2005): The mycotoxin Blue Book. Nottingham University Press, Nottingham.
- Fernandez, A., Verde, M. T., Gascon, M., Ramos, J. J. and Gomez, J. (1994). Aflatoxin and its metabolites in tissues from laying hens and broiler chickens fed a contaminated diet. J. Sci. Food. Agric.65: 407-414.
- Gathumbi, J. K., Usleber, E., Ngatia, T. A., Kangethe, E. K. and Ma'rtlbauer, E. (2003). Application of Immunoaffinity Chromatography and Enzyme Immunoassay in Rapid Detection of Aflatoxin B<sub>1</sub> in Chicken Liver Tissues. Poultry Science Association, Inc.
- Hsieh, D. P. (1983): "Metabolism and transmission of mycotoxins". Proc. Int. Symp. Mycotoxins. 6-8.
- Hussain, Z., Khan, M. Z. and Hassan, Z. (2008). Production of aflatoxins from *Aspergillus flavus* and acute aflatoxicosis in young broiler chicks Pak. J. Agri. Sci., Vol. 45(1)
- Kohler, H. (1963). Aflatoxin effects in poultry. Peoc. Xvii th. World Vet. Cong. Hannover. 1: 375.
- Lamont, M. H. (1979). "Cases of suspected mycotoxicosis as reported by veterinary investigation centers". Proc. Mycotoxins Anim. Dis. 3: 38-39.

- Lanza, G. M., Washburn, K. W. and Wyatt, R. D. (1980). "Strain variation in hematological response of broilers to dietary aflatoxin". *Poult. Sci.* 59: 2686-2691.
- Lawlor, P. G. and Lynch, P. B. (2005). Mycotoxin management. *African Farming and Food Processing.* 46:12-13.
- Logrieco, A., Battalico, A., Mulé, G., Moretti, A. and Perrone, A. (2003). Epidemiology of toxic fungi and their associated mycotoxins for some mediterranean crops. *European Journal of Plant Pathology,* 109: 645-667.
- Mintzlaff, H. J., Lotzsch, R., Tauchmann, F., Meyer, W. and Leistner, L. (1974). Aflatoxin residues in the liver and muscle of broiler chicken given aflatoxin containing feed. *Fleischwirtschaft.* 54: 774-778.
- Oruc, H. H., Cengiz, M. and Uzunoglu, I. (2007). Occurrence of Aflatoxin B1 and T-2 Toxin in feed and raw ingredients used for animal feeding stuffs. *Uludag Univ. J. Fac. Vet. Med.* 1 (2): 1-5
- Peterson, S. W., Ito, Y. B., Horn, W. and Goto. T. 2001. *Aspergillus bombycis*, a new aflatoxigenic species and genetic variation in its sibling species, *A. nomius*. *Mycologia* 93:689–703.
- Richard, J. L., Bennett, G.A., Ross, P. F. and Nelson, P. E. (1993). Analysis of Naturally occurring Mycotoxins in Feedstuffs and Food. *J. Anim. Sci.* 71: 2563-2574.
- Slowik, J., Graczyk, S. and Madej, J.A. (1985). " The effect of single dose of AFB<sub>1</sub> on the value of nuclear index of blood lymphocytes and on histopathological changes in the liver, bursa of fabricious, suprarenal glands and spleen in ducklings". *Folia Histochem. Cytobiol.* 3: 71-80.